

Banding Hemorrhoids Using the O' Regan Disposable Bander. Single Center Experience

Dimitrios Paikos¹, Anthie Gatopoulou¹, John Moschos¹, Anastasios Koulaouzidis², Shivram Bhat², Dimitrios Tzilves¹, Konstantinos Soufleris¹, Dimitrios Tragiannidis¹, Ioannis Katsos¹, Anestis Tarpagos¹

1) "Theagenio" Hospital, Thessaloniki, Greece. 2) Warrington General Hospital, Cheshire, UK

Abstract

Background. Hemorrhoids are the most common anorectal disorder in the Western World and are a major cause of active, relapsing or chronic rectal bleeding. Many treatment options have been proposed and tried for early-stage hemorrhoids. There is general agreement that rubber banding ligation (RBL) is safe and effective. **Aims.** To evaluate the effectiveness and complications associated with RBL performed in outpatients for symptomatic hemorrhoids using the O'Regan Disposable Bander device. **Results.** Sixty consecutive patients underwent hemorrhoid banding with the O'Regan Disposable Bander. The mean time required for one session was 6.2 min; the longest was 10 min. No major complications were noted. Minor early and late bleeding was reported in 10% and 6.7% respectively, but none was severe. Pain occurred in 6.7% but was not severe. In all cases, clinical and endoscopic (range and form scores) improvement was observed and patients of all ages, including the elderly, were found to be tolerant to the procedure. **Conclusion.** RBL performed in outpatients for symptomatic hemorrhoids using the O'Regan Disposable Bander device is associated with a good response and low complication rate. We recommend the technique as a safe and reliable treatment option.

Key words

Hemorrhoids - O'Regan disposable bander - rubber banding ligation

Introduction

Hemorrhoids are the most common anorectal disorder in the Western World (1). Many treatment options have been proposed and tried. There is general agreement that rubber banding ligation (RBL) is safe and effective. Surgery should

be reserved for 3rd or 4th grade hemorrhoids, "mixed" hemorrhoids not responding to RBL or patients on anticoagulants. The ideal treatment is easily learned, cost effective, gives satisfactory results and lacks complications. RBL is recommended as the initial mode of therapy for hemorrhoids of grade 1 to 3.

Our aim was to evaluate the effectiveness and complications associated with RBL performed in outpatients for symptomatic hemorrhoids using the O'Regan Disposable Bander device.

Material and methods

Between September 2005 and March 2006, 60 consecutive patients (32 men, 28 women) underwent RBL with the O'Regan Disposable Bander.

All patients had internal hemorrhoids of grade 1 to 4 (according to the Goligher grading system which is a four-stage grading for internal hemorrhoids) (2). All patients had undergone unsuccessful conservative treatment. The study design was approved by the hospital's Ethics Committee. Written informed consent was obtained from each patient. Patients with associated anal fissures, anal spasm or infectious anal pathologies and patients who refused to sign the informed consent form were excluded from the study.

All patients were prepared for treatment by administration of a saline solution enema and application of a local anesthetic ointment (Xylocaine Gel 2%; Astra Zeneca, Webel, Germany) into the anal canal. Early complications were defined as those occurring within a week.

All RBLs were performed on an outpatient basis. The front end of the loaded ligator was initially inserted fully into the rectum and then slowly withdrawn as it was angled acutely to point directly toward the site to be ligated, 1 cm above the dentate line. The tissue was sucked into the ligator by withdrawing its plunger. A test for pain was performed by rotating the ligator through 180° while maintaining suction. If this maneuver caused discomfort the ligator was repositioned at a higher level. Suction was maintained for at least 30 seconds while the ligator was rotated through 180° several times to allow an adequate bite of tissue to be

drawn inside the ligator. The band was then discharged with the band pusher and the vacuum was released (3). Ligations of as many hemorrhoids as possible were performed in this manner.

Range was determined by the circumferential distribution and classified into 5 stages as follows: stage 0: none, stage 1: a quarter of the circumference, stage 2: half of the circumference, stage 3: three quarters of the circumference, stage 4: the entire circumference.

Form was determined by the diameter of the largest hemorrhoid and classified into four sizes: size 0: none, size 1: less than 6 mm in diameter, size 2: between 6 and 12 mm in diameter, size 3: more than 12 mm in diameter.

Symptoms of bleeding, prolapse and pain were graded from 0 to 3 as follows: 0: none, 1: sometimes at defecation, 2: with every defecation; 3: irrespective of defecation (4).

Patients were evaluated for symptoms four weeks after the initial procedure and endoscopic examination was performed repeatedly to evaluate the range and the form of the internal hemorrhoids (4). Three months after the initial procedure patients were also evaluated for symptoms. Three-month response was graded as excellent (asymptomatic), good (definite improvement but occasional symptoms) and poor (no improvement, worsening of symptoms) (4).

Results

A mean of 1.9 bands were placed in a single session. The mean time required for one session was 6.2 min (range 3-10 min). The characteristics of our patients are shown in Table I.

Table I Patients' characteristics

No. of patients (%)	60 (100%)
Mean age (range) (years)	53.6 (76-33)
Gender ratio (male: female)	32:28
Alcohol consumption - No. (%)	4 (6.7%)
Smoking - No. (%)	14 (23.3%)
Mean body mass index (BMI)	22.9 (17.3-39) kg/m ²

Hemorrhoids were classified according to the Goligher classification as follows: grade 1: 6 (10%), grade 2: 36 (60%), grade 3: (26.6%) and grade 4: 2 patients (3.4%).

No major complications, such as massive bleeding or pelvic sepsis were noted. Early bleeding occurred in 6 patients (10%, 4 women, 2 men), but none was severe requiring transfusion or hospitalization. Pain was reported in 4 cases (6.7%, 4 women, 4 men). The pain was mild in three cases and moderate in the others.

Four patients (6.7%) reported bleeding between 10th and 12th day after banding, apparently due to detachment of the pile mass from the pedicle, both of which ceased spontaneously. Recurrent bleeding that necessitated a second session of ligation occurred in 4 cases. Clinical remission was maintained in all patients. The three-month response was excellent in 100% of patients with 1, 2 and 3 stage hemorrhoids. In the two cases of patients with stage

4 hemorrhoids the response was poor (no improvement) and surgical management was suggested.

In all cases, clinical and endoscopic (range and form scores) improvement was observed (Figs.1,2) and patients of all ages were found to be tolerant to the procedure.

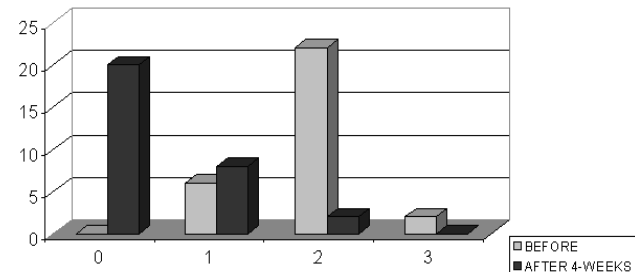


Fig.1 Distribution of patients according to form before O'Regan banding and 4 weeks after banding.

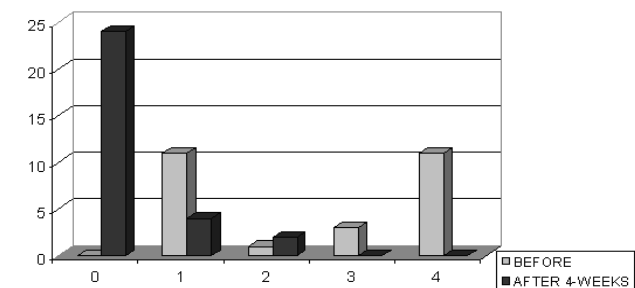


Fig.2 Distribution of patients according to range before O'Regan banding and 4 weeks after banding.

Discussion

Hemorrhoids are the most common anorectal disorder in the Western World and are a major cause of rectal bleeding (5). Many treatment options have been proposed and tried for early-stage hemorrhoids. There is general agreement that RBL is safe and effective (6). A method that could restore anal cushions to their normal size and position would be naturally preferred to methods that destroy tissue and interfere with the mechanisms of continence (7). Non-operative treatment is recommended for patients with symptoms caused by grade 1 to 3 hemorrhoids (8). RBL is recommended as the initial mode of therapy for hemorrhoids of grade 1 to 3 (3,9).

This study confirms that the technique using the O'Regan Disposable Bander device is quick, safe and effective in our population. The mean time required for one session was 6.2 min; the longest was 10 min. No major complications were noted. Minor early and late bleeding was reported, but none was severe. Pain occurred in 6.7%, but was not severe.

Urinary retention may occur in 10% to 50% of patients after surgical hemorrhoidectomy. One percent is the figure quoted by Schwartz as acceptable after banding, although he comments that as many as 10 to 20% of patients experience this after multiple ligations (10). There were no episodes of urinary retention or sepsis in our group. One recent study

suggests RBL for treatment for grade 2 hemorrhoids while reserving haemorrhoidectomy for grade 3 hemorrhoids or recurrences after RBL (11). Another recent study reported that RBL can be used to treat all degrees of hemorrhoids with similar effectiveness (12). In our study, 3-month follow-up was satisfactory regarding all grades of hemorrhoids apart from grade IV.

In conclusion, RBL performed in outpatients for symptomatic hemorrhoids using the O' Regan Disposable Bander device is associated with a good response and low complication rate. We recommend the technique as a safe and reliable treatment option.

Conflict of interest

None to declare.

References

1. Leff E. Hemorrhoids. *Postgrad Medicine* 1987; 82: 95-101.
2. Su MY, Chiu CT, Wu CS, et al. Endoscopic hemorrhoidal ligation of symptomatic internal hemorrhoids. *Gastrointest Endosc* 2003; 58: 871-874.
3. O' Regan PJ. Disposable device and a minimally invasive technique for rubber band ligation of hemorrhoids. *Dis Colon Rectum* 1999; 42: 683-685.
4. Fukuda A, Kayjiyama T, Arakawa H et al. Retroflexed endoscopic multiple band ligation of symptomatic internal hemorrhoids. *Gastrointest Endosc* 2004;59:380-384
5. Gupta PJ. Radiofrequency coagulation versus rubber band ligation in early hemorrhoids: pain versus gain. *Medicina (Kaunas)* 2004; 40: 232-237.
6. Cleator IG, Cleator MM. Banding Hemorrhoids Using the O' Regan Disposable Bander. *Business Briefing: US Gastroenterology Review* 2005: 69-73.
7. Gupta PJ. Infrared coagulation versus rubber band ligation in early stage hemorrhoids. *Braz J Med Res* 2003; 36: 1433-1438.
8. Pfenninger JL, Surrell J. Nonsurgical treatment options for internal hemorrhoids. *Am Fam Physician* 1995; 52: 821-834
9. MacRae HM, McLeod RS. Comparison of hemorrhoid treatment: a meta analysis. *Can J Surg* 1997; 40: 14-17.
10. Schwartz SI. *Principles of surgery*, 6th Ed., McGraw-Hill, N.York 1994 , pp, 222-1.229.
11. Shanmugam V, Thaha MA, Rabindranath KS, Campbell KL, Steele RJ, Loudon MA. Rubber band ligation versus excisional haemorrhoidectomy for hemorrhoids. *Cochrane Database Syst Rev* 2005;20: CD005034.
12. Iyer VS, Shrier I, Gordon PH. Long-term outcome of rubber band ligation for symptomatic primary and recurrent internal hemorrhoids. *Dis Colon Rectum* 2004; 47: 1364-1370.